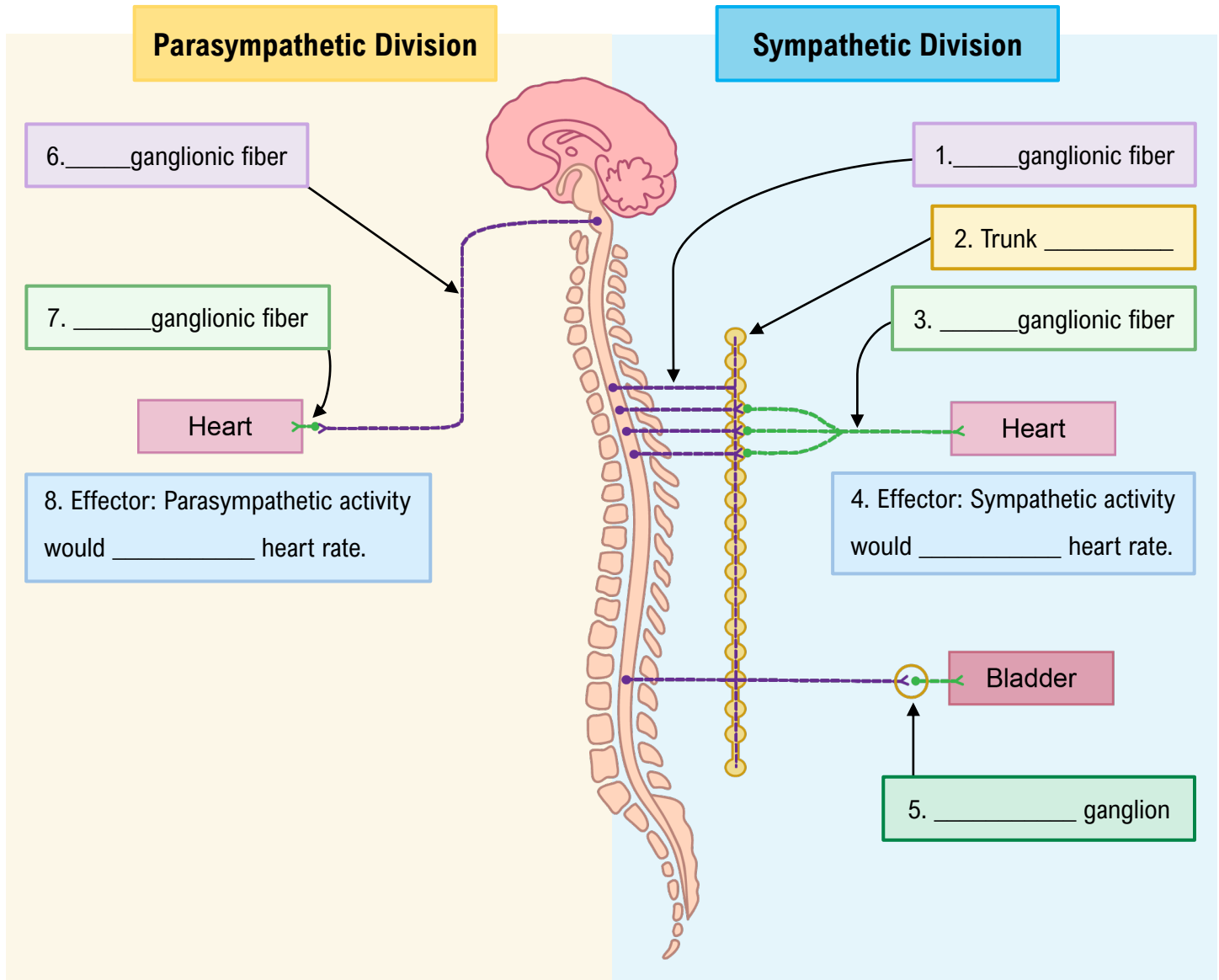


TOPIC: REVIEW OF THE SYMPATHETIC AND PARASYMPATHETIC DIVISIONS

- Let's review by examining dual innervation of the heart. Fill in the blanks in order, starting with the sympathetic division:



EXAMPLE: The sympathetic division contains a ganglionic _____ where many of its preganglionic fibers synapse. The parasympathetic division does not contain a similar structure. Instead, its preganglionic fibers can synapse in a _____ ganglion.

- Synapse; trunk.
- Trunk; terminal.
- Trunk; collateral.
- Chain; trunk.