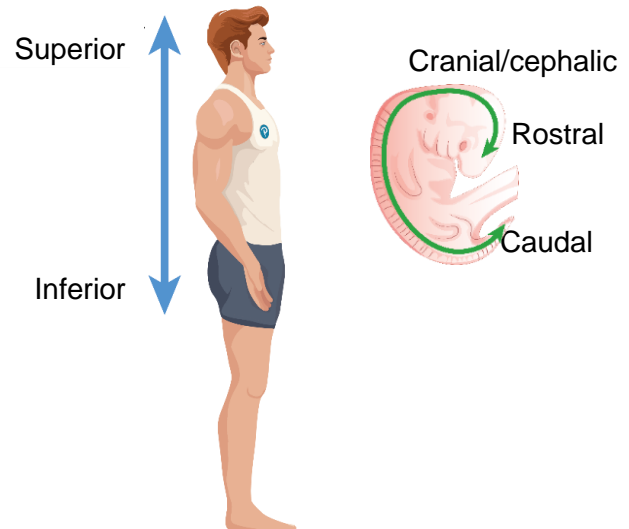


TOPIC: DIRECTIONAL TERMS: UP & DOWN

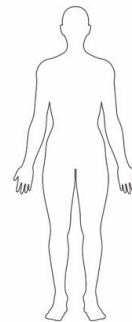
Up & Down

- More commonly used:
 - **Superior**: towards the _____.
 - **Inferior**: towards the _____.
- Less commonly used: Orient along spine from nose to tail.
 - **Rostral**: towards the nose/_____.
 - **Cranial/cephalic**: towards the head.
 - **Caudal**: Towards the _____.
 - Common in animal anatomy.
 - humans - used mostly for embryo/fetus.



EXAMPLE: On the body shown, place a(n):

- * Immediately superior to the left hip.
- O Immediately inferior to the chest.
- + Superior to the neck but inferior to the nose.
- X Immediately inferior to the shoulder.



PRACTICE: The pelvis is _____ to the ribs.

- a) Superior.
- b) Cranial.
- c) Rostral.
- d) Inferior.

PRACTICE: The atlas is the vertebra at the top of the spine that supports the head. The axis is the vertebra just under the atlas and it allows the head to swivel left and right. How are the atlas and axis arranged using correct terminology?

- a) The axis is superior to the atlas. The atlas is inferior to the axis.
- b) The atlas is cephalic to the axis. The axis is rostral to the atlas.
- c) The axis is inferior to the atlas. The atlas is superior to the axis.
- d) The axis is rostral to the atlas. The atlas is caudal to the axis.