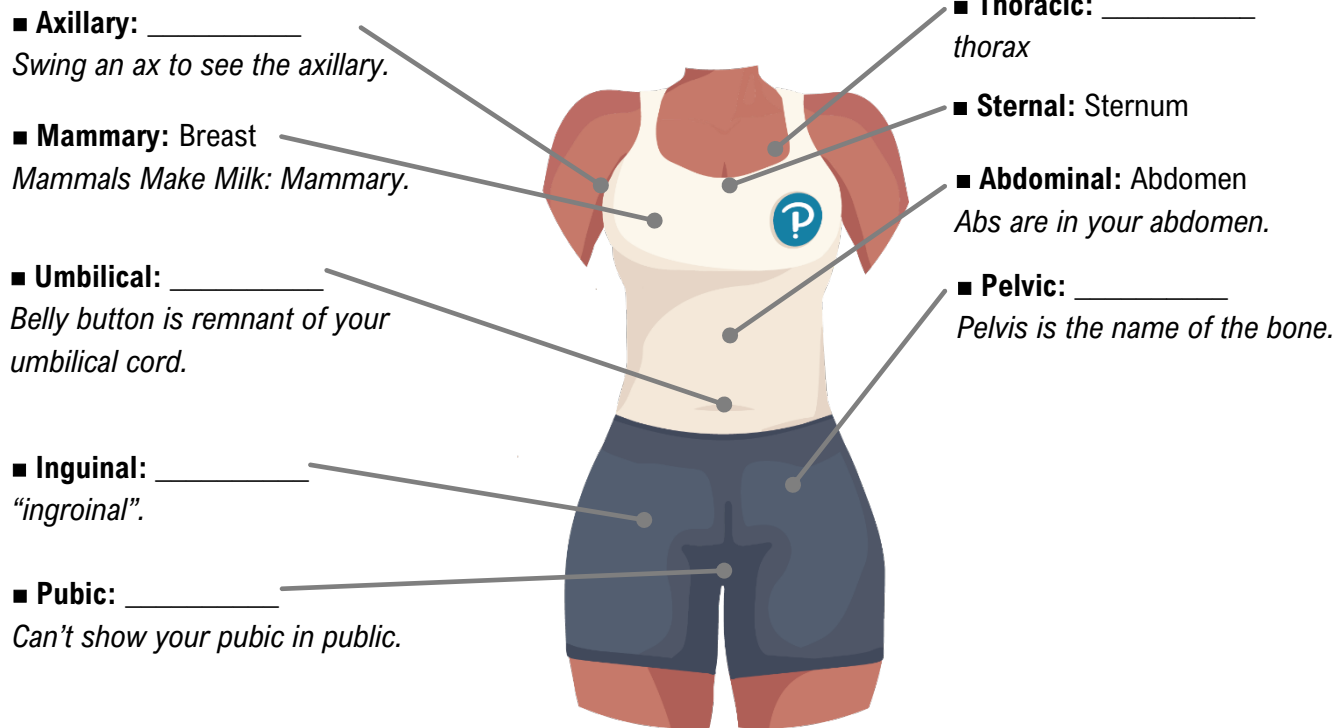


TOPIC: ANATOMICAL TERMS FOR THE FRONT OF THE TRUNK

Front of the Trunk



EXAMPLE: Use anatomical terms to identify where you think the following structures are located.

- | | | | |
|-------------------|-------|--------------------|-------|
| a) Mammary glands | _____ | c) Inguinal canal | _____ |
| b) Umbilical vein | _____ | d) Pubic symphysis | _____ |

PRACTICE: Which term or terms refers to an area that is inferior to the axillary region?

- a) Inguinal. b) Umbilical. c) Abdomen. d) A-C are correct.

PRACTICE: Your thoracic vertebrae are likely found in what region of the back based on the anatomical terms?

- a) Neck. b) Midback. c) Lower Back. d) Tailbone.

PRACTICE: If you experience an inguinal hernia while lifting a large box, what area will you grab in pain?

- a) Neck. b) Lower Back. c) Groin. d) Navel.