

TOPIC: THE PELVIC GIRDLE

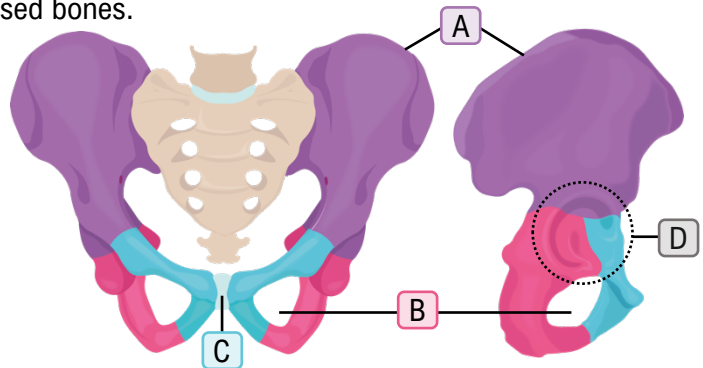
- **Pelvic girdle:** made of R & L coxal bones. **Pelvis** = coxal bones + _____.
- **Coxal bone** (_____) formed from _____ fused bones.

1. **Ilium:** Superior _____ region.

- **Iliac crest (A):** your hips.
- "I like your iliac crest" = nice.

2. **Ischium:** lower _____ region.

- Forms **Obturator Foramen (B)** with pubis.
- large hole in coxal bone.
- Bones you sit on — _____ bones.
- Round**ISH** ischium is in your rear.



3. **Pubis:** lower _____ region.

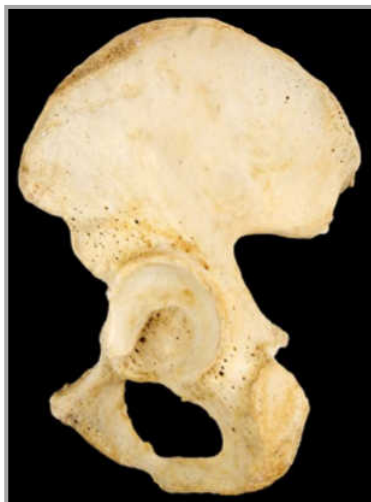- **Pubic symphysis (C):** _____ between R&L pubis.
- The pubis is pointy.

Acetabulum (D): hip _____; formed by all 3 bones.

- With pubis pointing front, acetabulum is to the _____.

EXAMPLE: On the diagram below, label the three smaller bones that make up the coxal bone and identify whether the left or right coxal bone is shown.

Right or Left: _____



PRACTICE: On which bone is the acetabulum found?

- a) Ilium.
- b) Ischium.
- c) Pubis.
- d) A-C are all correct.

TOPIC: THE PELVIC GIRDLE

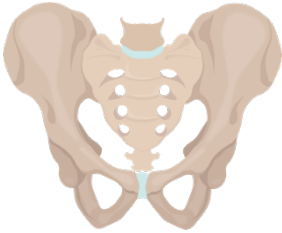
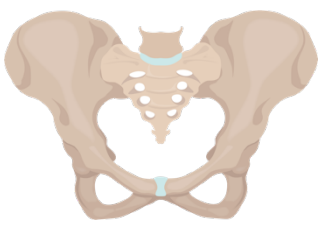
PRACTICE: When comparing the pelvic and pectoral girdles, which statement is *incorrect*?

- a) The articulation between the pectoral girdle and the axial skeleton is smaller than the articulation between the pelvic girdle and the axial skeleton.
- b) The socket of the hip joint is much deeper than the socket of the shoulder joint.
- c) There are more individual bones in the pectoral girdle than the pelvic girdle.
- d) The pelvic girdle allows for a greater range of motion than the pectoral girdle.

TOPIC: THE PELVIC GIRDLE

Differences Between the Male and Female Pelvis

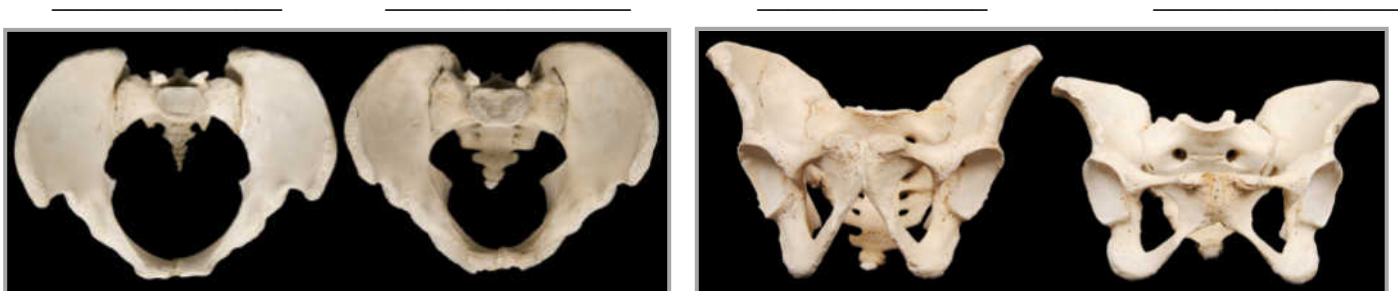- The _____ of the pelvis differs between males and females.

	Male		Female	
General Appearance	Narrow & _____.		_____ & lighter.	
Angle of Pubic Arch	_____		_____	
Shape of Pelvic Inlet	_____ & closer together.		_____ & further apart.	

- Female pelvis adapted for _____.

EXAMPLE: Below, four pelvises are shown. Two are shown from the front and two are shown from above. In each view, one pelvis is from a female and one is from a male. Identify which pelvises you believe to be male and which you believe to be female. Then, indicate at least one anatomical feature that allowed you to differentiate the two by marking it on the picture.

Likely sex:



PRACTICE: How does the angle of the pelvic arches differ in male and female pelvises?

- The angle of the male pelvic arch tends to be more acute than the female pelvic arch.
- A female's pelvic arch tends to be rounder to accommodate the head of the baby.
- The female pelvic arch tends to be more heart shaped than the male pelvic arch.
- The pelvic arch is not a reliable indicator of sex.